

( )

\*

:

/ / /

:

\*



:

)

.(

.( )

.( )

pH

.( )

.( )

)

(

.( )

.( )

( )

.( )

---

(Intra

/ / /

dermal)

:

:

/

)

/

(

:

LA RA

LL RL

III II I

aVF aVL aVR

Hewlett

packard

(Long lead)

II

(.)

:

(P > / )

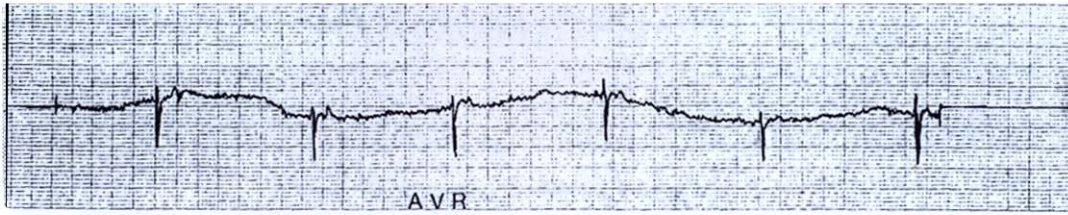
:



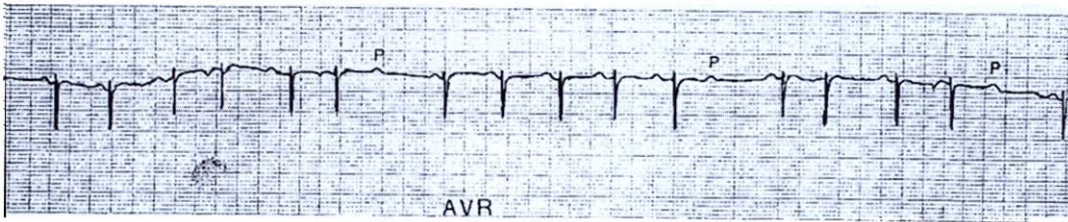
تصویر ۱: عقرب ادنتوبوتوس دورویه



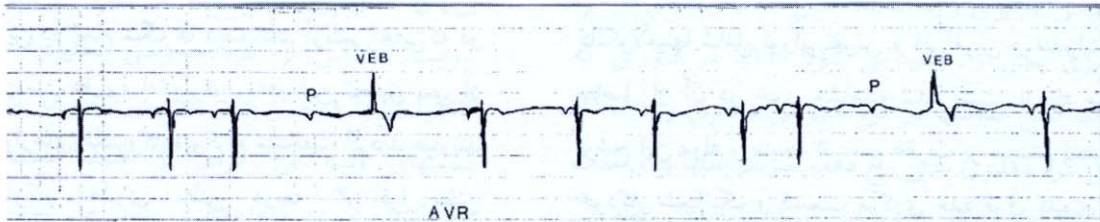
تصویر ۲: آریتمی سینوسی (نرمال) در سگ های سالم



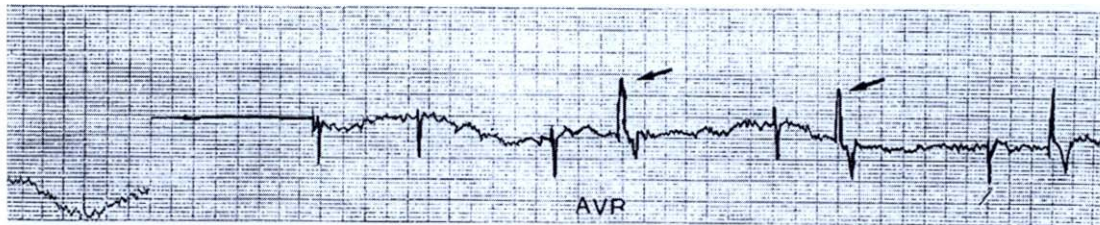
تصویر ۳: برادی کاردی شدید ۹۰ دقیقه پس از تزریق سم.



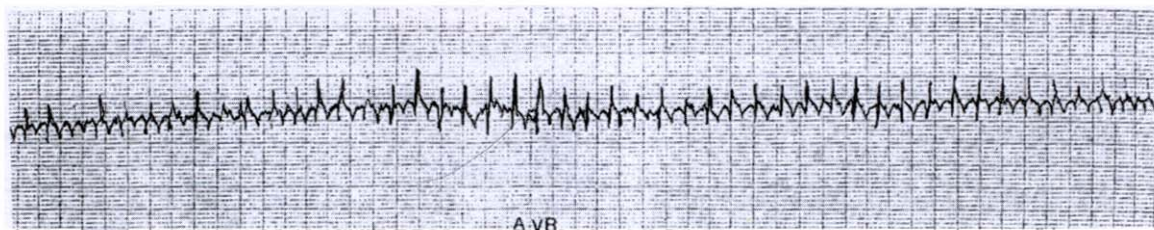
تصویر ۴: بلوک دهلیزی بطنی درجه ۲ در ۳۰ دقیقه پس از تزریق سم.



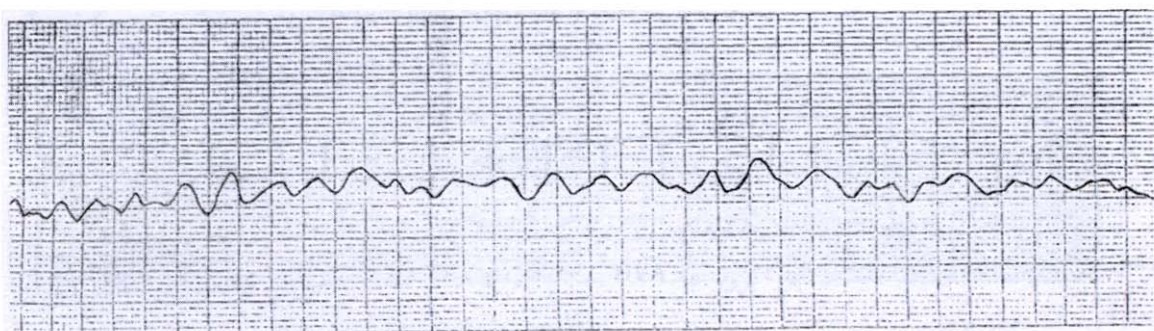
تصویر ۵: فرار بطنی (Ventricular escape) و بلوک دهلیزی بطنی درجه ۲ در ۳۰ دقیقه پس از تزریق سم.



تصویر ۶: انقباضهای زودرس بطنی ۱۸۰ دقیقه پس از تزریق سم.



تصویر ۷: تاکیکاردی بطنی ۶۰ دقیقه پس از تزریق سم.



تصویر ۸: فیبرولاسیون بطنی در دقیقه ۹۰.

)

.

:

(Ventricular escape)

( )

QRS

P

.

.

T

:

:

---

(Premature ventricular

.( )

.contraction)

:

T

P-R

QRS

S-T

) R S

P

.(

.( )

:

( )

K<sup>+</sup>

K<sup>+</sup>

.( )

.( )

( )

(Ventricular escape)

.( )

)

( )

.(

( )

( ) .

( )

T

P

S-T

QRS

T

:

T

S-T

T

QRS

.( )

:

( )

**References :**

- :( )
2. Fowler ME. Veterinary zootoxicology. CRC Press. Inc. Boca Racton, 1993, 81-87.
  3. Sherman MA. Venom Disease. Springfield, Illinois, Charles, Thomas, Pub, 1974, 27-37.
  5. Dehesa-Davila, M. Possani LD. Scorpionism and serotherapy in Mexico. Toxicon 1994; 32: 1015-1018.
  6. Radmanesh M. *Androctonus Crassicauda* sting and its clinical study in Iran. J Trop Med Hyg 1990; 93: 323-326.
  7. Parrish HM. Analysis of 460 fatalities from venomous animals in the United States. Am J Med Sci 1963; 245: 129-141.
  8. Tiwary AK, Deshpande S B. Toxicity of scorpion (*Buthus tamulus*) venom in mammals is influenced by the age and species. Toxicon 1993; 31: 1619-1622.
  10. Amaral CFS, Barbosa AJA, Leite VH. R, et al. Scorpion sting-induced pulmonary oedema: evidence of increased alveolocapillary membrane permeability. Toxicon 1994; 32: 999-1003.
  11. Bawaskar HS, Bawaskar PH. Cardiovascular manifestations of severe scorpion sting in India (review of 34 children). Ann Trop Paediat 1991; 11: 381-387.



- 
12. Bawaskar HS, Bawaskar PH. Treatment of cardiovascular manifestations of human scorpion envenoming: is serotherapy essential? *J Trop Med Hyg* 1991; 94: 156-158.
  13. Bawaskar HS, Bawaskar PH. Role of atropine in management of cardiovascular manifestations of scorpion envenoming in humans. *J Trop Med Hyg* 1992; 95: 30-35.
  14. Bawaskar HS, Bawaskar PH. Management of the cardiovascular manifestations of poisoning by the Indian red scorpion (*Mesobuthus tamulus*). *Br Heart J* 1992. 68: 478-480.
  15. Ismail M, Fatani AJY, Dabees TT. Experimental treatment protocols for scorpion envenomation: a review of common therapies on effect of kallikrein-Kinin inhibitors. *Toxicon* 1992;30:1257-1279.
  16. Kumar EB, Al-Hamdani A, El. Shimy N. Scorpion venom cardiomyopathy. *Am Heart J* 1992; 123: 725-729.
  17. Murthy KRK, Sheno R, Vaidyanathan P, et al. Insulin reverts haemodynamic changes and pulmonary oedema in children stung by the Indian red scorpion *Mesobuthus tamulus* Concanesis pocock. *Ann. Trop Med Parasitol* 1991; 85: 651-657.
  18. Gateau T, Bloom M, Clark R. Response to specific *Cetrurioides sculpturatus* antivenom in 151 cases of scorpion stings. *J Toxicol Clin Toxicol* 1994; 32: 165-171.
  19. Guyton AC. *Textbook of Medical Physiology*. 9<sup>th</sup> ed. W. B. Saunders: Philadelphia, 1996, 121-158.
  20. Amaral CFS, Lopes JA, Magalhaes R A, et al. Electrocardiographic, enzymatic and echocardiographic evidence of myocardial damage after *Tityus serrulatus* scorpion poisoning. *Am J Cardiol* 1991; 67: 655-657.
  21. Freire-Maia L, Campos JA, Amaral C FS. Approaches to the treatment of scorpion envenoming. *Toxicon* 1994;32: 1009-1014.
  22. Gueron M, Ovsyshcher I. What is the treatment for the cardiovascular manifestations of scorpion envenomation. *Toxicon* 1987; 25: 121-125.
  23. Murthy K, Radha K, Hase NK. Scorpion envenomation and the role of insulin. *Toxicon* 1994; 32: 1041-1044.
  24. Poon-King T. Myocarditis from scorpion stings. *Br Med J* 1963; 1: 374-377.
  25. Radmanesh M. Clinical study of *Hemiscorpion lepturus* in Iran *J Trop Med Hyg* 1990; 93: 327-332.